

Human Paragonimiasis in North America following Ingestion of Raw Crayfish

Michael A. Lane,¹ Mary C. Barsanti,¹ Carlos A. Santos,¹ Michael Yeung,² Sam J. Lubner,² and Gary J. Weil¹

¹Infectious Diseases Division and ²Department of Internal Medicine, Washington University, St. Louis, Missouri

Paragonimiasis (human infections with the lung fluke *Paragonimus westermani*) is an important public health problem in parts of Southeast Asia and China. Paragonimiasis has rarely been reported from North America as a zoonosis caused by *Paragonimus kellicotti*. *Paragonimus* species have complex life cycles that require 2 intermediate hosts, namely, snails and crustaceans (ie, crabs or crayfish). Humans acquire *P. kellicotti* when they consume infected raw crayfish. Humans with paragonimiasis usually present with fever and cough, which, together with the presentation of hemoptysis, can be misdiagnosed as tuberculosis. Only 7 autochthonous cases of paragonimiasis have been previously reported from North America. Our study describes 3 patients with proven or probable paragonimiasis with unusual clinical features who were seen at a single medical center during an 18-month period. These patients acquired their infections after consuming raw crayfish from rivers in Missouri. It is likely that other patients with paragonimiasis have been misdiagnosed and improperly treated. Physicians should consider the possibility that patients who present with cough, fever, hemoptysis, and eosinophilia may have paragonimiasis.

Paragonimiasis is an infection caused by trematode parasites of the genus *Paragonimus*. Patients with paragonimiasis usually present with signs and symptoms in the lower respiratory tract. At least 9 species have been identified that cause infections in humans [1]. *Paragonimus westermani* is an important pathogen in Southeast Asia and China [2]. Paragonimiasis is uncommon among North Americans who have not traveled or lived in endemic areas in the far east. Most North American cases of paragonimiasis are caused by *Paragonimus kellicotti* [3]. *P. kellicotti* infections in bobcats [4], raccoons [5], gray foxes [6], red foxes [7], skunks [7], mink [7, 8], coyotes [7], cats, and dogs have been reported. The purpose of our study is to describe 3 recent North American cases of paragonimiasis at a large teaching

hospital and to review the clinical features of paragonimiasis in North America.

CLINICAL CASES

Patient 1

Patient 1 was a previously healthy 26-year-old female who presented to her local hospital with a 2-week history of fatigue, malaise, cough, fevers, night sweats, and vomiting. She was admitted to her local hospital and given a working diagnosis of community-acquired pneumonia. She was treated with levofloxacin and discharged from the hospital.

She returned to the hospital when her symptoms persisted. Laboratory studies at that time showed a peripheral eosinophil count of 2000 cells/mm³ (eosinophil percentage, 20%). She underwent bronchoscopy with transbronchial biopsy. The biopsy demonstrated an eosinophilic inflammatory infiltrate. Bronchoalveolar lavage (BAL) also demonstrated eosinophilia. Routine BAL culture, mycobacterial culture, and fungal culture results were negative. Methylprednisolone therapy was initiated for a presumed diagnosis of eosinophilic pneumonia.

The patient's symptoms improved with the use of steroids. However, her fevers, chills, night sweats, and

Received 19 March 2009; accepted 17 May 2009; electronically published 14 August 2009.

Reprints or correspondence: Dr. Michael A. Lane, Washington University School of Medicine, 660 S. Euclid Ave., Campus Box 8051, St. Louis, MO 63110 (mlane@dom.wustl.edu).

Clinical Infectious Diseases 2009;49:000–000

© 2009 by the Infectious Diseases Society of America. All rights reserved.

1058-4838/2009/4906-00XX\$15.00

DOI: 10.1096/605534

malaise returned when use of steroids was tapered. She also developed a 0.5-cm nodular lesion inferior to her left lower lip. A needle biopsy demonstrated an inflammatory infiltrate with conspicuous eosinophils. The lesion grew in size to 1.5 cm and migrated to her left cheek.

She was referred to our tertiary care hospital for further evaluation. Physical examination was notable for detecting a 2-cm firm, nontender mobile mass on the left cheek. Breath sounds were diminished at the left base. The remainder of her physical examination was normal. Her white blood cell count was 6200 cells/mm³, with an absolute eosinophil count of 800 cells/mm³ (eosinophil percentage, 13.7%). A computed tomography (CT) scan (figure 1) revealed a left pleural effusion and a focal opacity at the apex of the left lower lung lobe. Serum samples tested negative for *Rickettsia*, *Ehrlichia*, and *Strongyloides* species as well as for Epstein-Barr virus, herpes simplex virus, cytomegalovirus, and human immunodeficiency virus. Patient 1 was unable to provide a sputum specimen despite repeated attempts at sputum induction.

Upon further questioning, the patient revealed that she had been on a “float trip” on a tributary of the Meramec River in southeastern Missouri ~4 weeks before the onset of her symptoms. She also stated that she had eaten 2 uncooked crawfish from the river while intoxicated. Two weeks after returning from the float trip, she developed a self-limited diarrheal illness. She later experienced fatigue, malaise, cough, fevers, night sweats, and vomiting. An enzyme-linked immunosorbent assay (ELISA; developed by Parasitic Disease Consultants) was positive for *Paragonimus* species at 1:32. The patient received a diagnosis of paragonimiasis and was treated with praziquantel 75 mg/kg in 3 divided doses for 2 days. Her systemic symptoms resolved within 48 h of initiating therapy, and the left cheek mass resolved within 7 days of treatment. Treatment with methylprednisolone was tapered and discontinued. One month after treatment, the patient denied having symptoms of fever, night sweats, cough, or malaise. A complete blood cell count at that time revealed a total white blood cell count of 5700 cells/mm³ with a normal eosinophil count.

Patient 2

Patient 2 was a previously healthy 32-year-old male who presented with a 3-month history of recurrent fevers (with temperatures as high as 39.5°C [103°F]), myalgias, arthralgias, generalized malaise, and cough producing minimal brownish sputum. The patient also noticed an indurated tender nodule on the dorsal surface of his left fourth distal interphalangeal joint. His primary care physician ordered a chest radiograph that showed hazy bilateral upper lobe infiltrates and small bilateral pleural effusions. He was treated with levofloxacin for 7 days for presumed community-acquired pneumonia.

The patient’s symptoms persisted while on levofloxacin. In

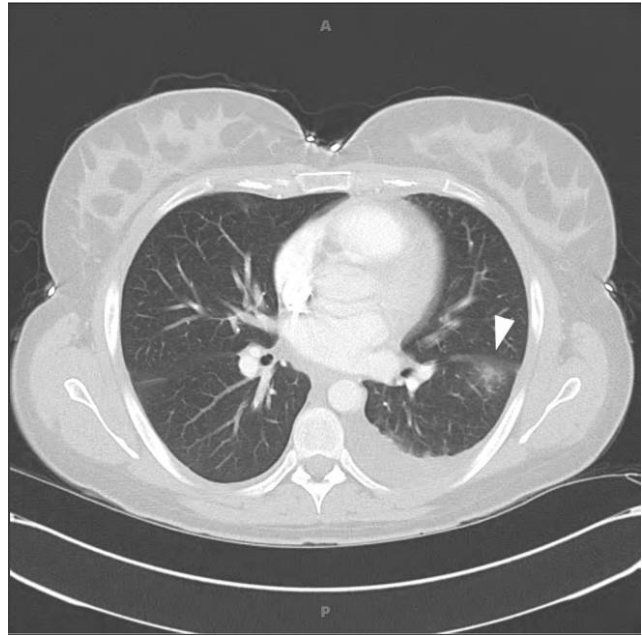


Figure 1. Computed tomography scan of the chest of patient 1 showing a focal consolidation in the superior segment of the left lower lobe (arrowhead) and a left pleural effusion.

addition, he developed diffuse headaches and blurred vision. He described the headaches as “sharp” and “splitting.” In addition, he also reported abnormal vision with intermittent blind spots and floaters. He was admitted to a community hospital where cerebral spinal fluid analysis and CT scan of the head were normal. A complete blood cell count revealed a white blood cell count of 12,000 cells/mm³ with an absolute eosinophil count of 3600 cells/mm³ (eosinophil percentage, 30%). The findings of basic chemistry and liver function tests were all normal. All blood and urine culture results were negative. Bronchoscopy was performed, and BAL revealed eosinophilia. He was given a diagnosis of eosinophilic pneumonia and treated with prednisone 60 mg daily. Steroid therapy initially improved his symptoms; however, his symptoms returned when his steroid dose was decreased.

The patient was referred to our hospital for further evaluation of his symptoms. His physical examination was significant for the detection of an indurated, tender nodule on the volar aspect of his left fourth distal interphalangeal joint. The patient reported that the nodule was migratory. The findings of a neurologic examination were normal. A complete blood cell count showed a white blood cell count of 10,100 cells/mm³ with an absolute eosinophil count of 3000 cells/mm³ (eosinophil percentage, 30%). Serum samples tested negative for *Rickettsia*, *Ehrlichia*, and *Strongyloides* species as well as for Epstein-Barr virus, herpes simplex virus, cytomegalovirus, and human immunodeficiency virus. A chest radiograph showed bilateral upper lobe infiltrates, and a magnetic resonance imaging of the

brain (figure 2) showed an enhancing lesion in the right occipital lobe.

Upon further questioning, the patient reported eating raw crayfish while intoxicated during a float trip on the Current River in southern Missouri ~3 weeks before the onset of his symptoms. An ELISA performed at the Centers for Disease Control and Prevention was positive for *Paragonimus* species. The patient was treated with a 3-day course of praziquantel 75 mg/kg in 3 divided doses for pulmonary, cutaneous, and probable cerebral paragonimiasis. His symptoms resolved within 3 days of starting therapy. After 1 month of follow-up, the patient was free of symptoms. A complete blood cell count showed resolution of his leukocytosis and eosinophilia.

Patient 3

Patient 3 was a previously healthy 31-year-old male who presented with a 2-week history of fevers and pharyngitis. He was seen at an urgent care facility where a monospot test and a rapid streptococcal antigen test were performed, both of which were negative. After several days of continued symptoms, the patient was evaluated at his local emergency department. The findings of a lumbar puncture, a blood culture, and a chest radiograph were within normal limits. The patient was discharged from the emergency department with a 7-day course of doxycycline for a presumed tick-related infection.

The patient completed the course of doxycycline but continued to have fevers. In addition, he developed chills, rigors, night sweats, headaches, and shortness of breath. The patient was prescribed cefuroxime, which did not alter his symptoms. The patient had continued fevers and worsening shortness of breath. He also reported diffuse chest pain and weight loss. He denied having abdominal pain, nausea, vomiting, skin changes, arthritis or arthralgias.

The patient presented to our tertiary care hospital with con-

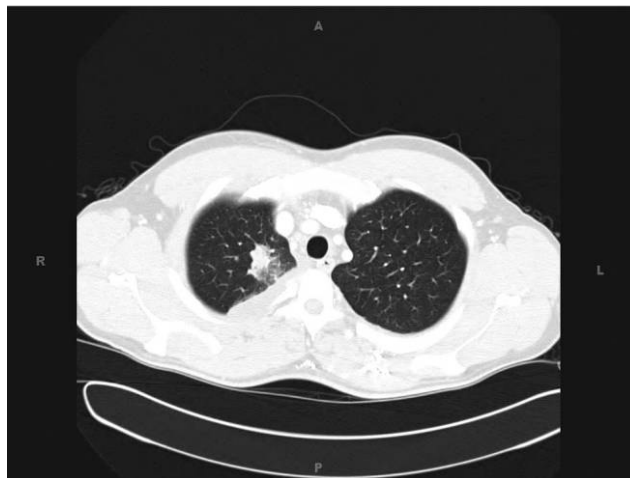

Figure 3. Computed tomography scan of the chest of patient 3 showing a right apical mass.

tinued fever, chills, shortness of breath, and cough. A physical examination revealed a temperature of 39.2°C and diminished breath sounds at the right lung base. The remainder of the findings of the examination were within normal limits. Laboratory studies revealed a white blood cell count of 11,300 cells/mm³ with an absolute eosinophil count of 2300 cells/mm³ (eosinophil percentage, 20%). A chest radiograph revealed a right-sided pleural effusion. A CT scan of the chest showed a right pleural effusion and an apical mass in the right lung (figure 3). A thoracentesis was performed. Pleural fluid analysis showed 5.6 g/dL of protein, 2074 IU/L of lactate dehydrogenase, and <30 mg/dL of glucose. The total cell count in the pleural fluid was 44,650 cells/ μ L, with a nucleated cell count of 14,650 cells/ μ L (18% neutrophils, 8% lymphocytes, 6% monocytes, and 68% eosinophils). Gram stain of pleural fluid specimen showed abundant neutrophils but no organisms. Pleural fluid culture

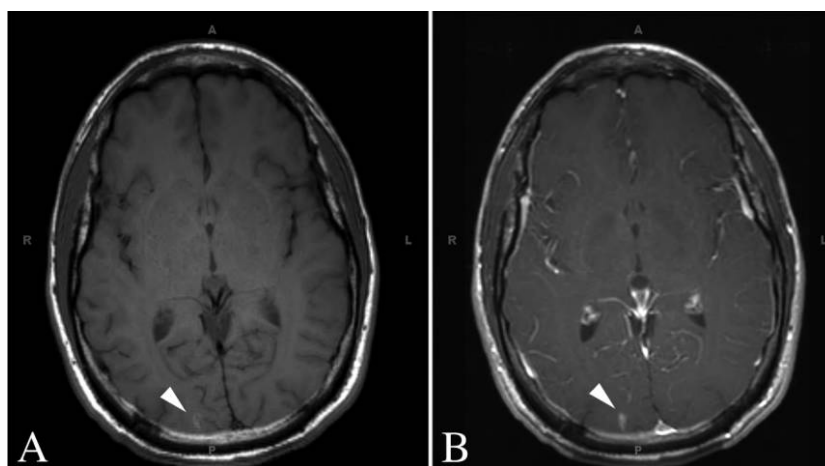


Figure 2. Magnetic resonance imaging (MRI) of the brain of patient 2 showing a 7 × 4 × 2 mm lesion in the right occipital lobe (arrowhead). A, T1-weighted brain MRI. B, Postcontrast enhancement of right occipital lobe lesion.

results for bacteria, fungus, and acid-fast bacilli were negative. A pleural biopsy revealed abundant histiocytes with poorly formed granulomas. Patient 3 had a serum protein level of 7.2 g/dL and a lactate dehydrogenase level of 157 IU/L.

The patient reported that he had visited Cancun, Mexico, 6 weeks before the onset of his symptoms. He spent 5 days at a resort where he ate food prepared at the resort and drank only bottled water. The patient was initially treated with doxycycline and primaquine without improvement in his symptoms. Further questioning revealed that the patient had gone on a float trip on the Jacks Fork and Current Rivers in southeastern Missouri 1 week after his return from Cancun and that he had consumed 2 raw crayfish while intoxicated during this outing. His symptoms began ~4 weeks after consuming the raw crayfish. Treatment with doxycycline and primaquine was discontinued, and the patient was treated with praziquantel 75 mg/kg in 3 divided doses for 2 days. The patient defervesced, and his symptoms resolved promptly after treatment with praziquantel.

Serum samples obtained during his hospitalization and 2 months after treatment tested negative for antibodies to *P. westermanii* using an ELISA performed at the Centers for Disease Control and Prevention. Another chest radiograph 3 weeks after hospital discharge showed resolution of the right apical infiltrate. All symptoms and the eosinophilia had resolved by the time of his 2-month follow-up visit.

DISCUSSION

In 1894, Drs. Ward and Kellicott described *Paragonimus* parasites in lung tissue from a dog in Ohio and a cat in Michigan [3, 9, 10]. Ward distinguished North American *Paragonimus* worms from those found in Asia, on the basis of differences in morphology, and named the new species *P. kellicotti*. Subsequent investigators have confirmed these morphological differences [11, 12]. While molecular phylogenetic analyses have been performed on *Paragonimus* species endemic to Asia [13, 14], this has not been done yet for *Paragonimus* species from North America.

Paragonimus lung flukes have a complex life cycle that require 2 intermediate hosts and 1 definitive host. Eggs excreted in stool hatch in water to become ciliated miracidia that invade the soft tissue of snails, the first intermediate host [15]. The parasite develops in snails to become cercariae, which leave the snail and invade the second intermediate host. The second intermediate host for *P. kellicotti* are crayfish of the genera *Cambarus* and *Orconectes*. The cercariae encyst in muscle and become metacercariae. When ingested by the appropriate definitive host, the metacercariae excyst in the duodenum and migrate to the lungs, where they mature into adult worms that produce eggs. *P. kellicotti* has a wide host range that includes carnivores (such as mink, muskrat, and opossum) and domestic animals (such as cats and dogs). Humans are accidental hosts.

Human infections with the *Paragonimus* species have been identified in many parts of the world, but they are most common in eastern Asia. It is estimated that 292.8 million people worldwide are at risk for infection with *Paragonimus* species, with 195 million people at risk in China [16]. Seroprevalence in China ranges from 1.9% in Anhui and Liaoning Provinces to 33.7% in Jilin Province [2]. Paragonimiasis in humans is uncommon in North America, with only 7 cases previously described in patients who acquired the infection without traveling abroad or eating imported food items (table 1). Our patients were infected by eating uncooked crayfish from rivers in Missouri.

Humans acquire *Paragonimus* infections when they consume metacercariae from uncooked shellfish, such as crabs and crayfish. People in parts of eastern Asia commonly eat raw or alcohol-cured crustaceans [24], and this explains the high incidence of paragonimiasis in that region. In contrast to Asia, consumption of raw crustaceans is uncommon in North America. It is very likely that alcohol played a role in our cases by relaxing normal dietary inhibitions. The distribution of *P. kellicotti* in North America has not been mapped in detail, but the parasite is known to be widely distributed in the midwest region of the United States. Most previously reported cases have been from this region.

P. westermani infections can cause a variety of clinical symptoms. Early infections are often asymptomatic, and it is likely that some infected persons never present with clinical disease. Pulmonary symptoms typically present months after infection (range, 1–27 months; mean, 6 months) [25]. Cough and hemoptysis are common (seen in 60%–100% of patients) [26–29]. Fever is also common (11%–67% of patients) [26–28]. Given this constellation of symptoms, it is not surprising that paragonimiasis is often confused with tuberculosis [26–28]. Cough, fever, and hemoptysis are also common in patients with *P. kellicotti* infection (table 1). *Paragonimus* flukes sometimes migrate to ectopic locations, including the central nervous system (CNS) [30]. Patients with CNS involvement often report headaches as the presenting symptom. Our patient 2 experienced headaches and had abnormal findings on magnetic resonance imaging consistent with paragonimiasis of the CNS. To our knowledge, this is the first described case of *P. kellicotti* infection with probable CNS involvement. Seizures occur in 40% of patients with CNS involvement, and many patients (55%) have impaired vision and/or visual field deficits. CNS symptoms may present months after the onset of pulmonary symptoms [30]. *Paragonimus* species can also migrate to subcutaneous tissue and cause subcutaneous nodules in up to 20% of patients with *P. westermani* infection [26, 28, 31]. Our patients 1 and 2 had migratory skin nodules; to our knowledge, this has not previously been reported for cases of *P. kellicotti* infection.

Many patients with *P. westermani* infections have normal

Table 1. Characteristics of Patients With Paragonimiasis in North America

Age and sex of patient	Geographic location	Risk factor	Presentation	Method of diagnosis	Study
51-year-old male	Montreal, Canada	Snails and crustacean	Fatigue, dyspnea, and malaise	Lung surgical pathology; sputum cytology	Beland et al [17]
19-year-old male	Current River, Missouri	Crayfish	Fatigue, fever, dyspnea, eosinophilia, and pleural effusion	Sputum cytology; serology	Pachucki et al [18]; Mariano et al [19]
21-year-old male	Arkansas River	Crayfish	Hemoptysis and cough	Sputum cytology	Procop et al [20]
18-year-old male	Michigan	Crayfish	Fatigue, dyspnea, pleural effusion, and eosinophilia	Pleural surgical pathology; serology	DeFrain and Hooker [21]
35-year-old male	Arkansas River, Oklahoma	Crayfish	Hemoptysis, cough, pneumothorax, and pleural effusion	Pleural surgical pathology	Castilla et al [1]
71-year-old male	Iowa	Crayfish	Dyspnea and pleural effusion	Pleural fluid cytology	Madariaga et al [22]
31-year-old male	Denver, Colorado	Unknown	Chronic cough, hemoptysis, dyspnea, and eosinophilia	Lung surgical pathology	Boe and Schwarz [23]
26-year-old female (patient 1)	Meramec River, Missouri	Crayfish	Fatigue, cough, fever, and eosinophilia	Serology	Our study
32-year-old male (patient 2)	Current River, Missouri	Crayfish	Fever, malaise, cough, headache, and eosinophilia	Serology	Our study
31-year-old male (patient 3)	Jacks Fork and Current Rivers, Missouri	Crayfish	Fever, pharyngitis, cough, dyspnea, and eosinophilia	Clinical history	Our study

physical examinations [31]. Others may have nonspecific findings such as rales or rhonchi in the chest (present in up to 28% of patients) [27]. Laboratory abnormalities include leukocytosis (24%–33% of patients) [26–28] and eosinophilia (62%–66% of patients) [27, 28]. A similar percentage of North Americans with paragonimiasis had eosinophilia (6 [75%] of 8 patients). Radiographic abnormalities are common among patients with paragonimiasis in Asia, with 52% of patients having air-space consolidation and 37% of patients having pleural effusions [32]. All 10 North American patients demonstrated abnormal chest radiographic findings, including “nonspecific linear streaking” [20], pneumothorax (1 patient) [18], pleural effusion (6 patients) [18, 19, 21, 22], and consolidation or an infiltrate (7 patients) [1, 18, 19, 21–23].

It is difficult to make a direct parasitological diagnosis of paragonimiasis by microscopy. Although the presence of ova in expectorated sputum is specific, the sensitivity of this test is low (28%–38%). Repeat sputum examinations may increase the sensitivity of this test [28]. Stool examination is also insensitive [31], and ova are not usually found in pleural fluid [28, 31]. Pleural fluids commonly have low glucose levels (<10 mg/dL) and high total protein levels (>3 g/dL) [28]. Pleural fluid white blood cell counts are often >1000 cells/mm³ [28, 33].

Serological testing is useful for establishing the diagnosis of paragonimiasis. The Centers for Disease Control and Prevention perform an ELISA that is highly sensitive (96%) and specific (99%) for *P. westermani* [34]. The sensitivity of this test for serum samples from patients with other species of *Paragonimus* infection, including *P. kellicotti*, is unknown. This may explain the negative test result from patient 3. Despite his negative test result, patient 3’s history, clinical presentation, and response to praziquantel therapy were consistent with the diagnosis of paragonimiasis. Patients 1 and 2 in our study both had an ELISA that was positive for *P. westermani*.

The current recommended treatment for paragonimiasis is praziquantel 25 mg/kg given orally 3 times daily for 2 days. Cure rates of >95% have been reported [35]. All 3 of our patients had excellent clinical responses to praziquantel, with improved symptoms and resolution of eosinophilia.

In summary, although paragonimiasis is considered to be rare among humans in North America, we cared for 3 patients with proven or probable paragonimiasis at a medical center during an 18-month period. All 3 patients had recently ingested raw crayfish from rivers in Missouri. It is likely that other cases of paragonimiasis have been recognized and treated in this region, but not reported. More troubling, it is also likely that some patients with paragonimiasis have been misdiagnosed and, therefore, were not properly treated. This infection is easily avoidable; public health education messages should warn people not to ingest uncooked crayfish. Our local cases show that alcohol use, boating, and the consumption of raw cray-

fish can be a dangerous mixture. Health warnings might have the greatest impact if they were posted or distributed at campgrounds and canoe rental businesses in the lower midwest. Physicians should consider the possibility of paragonimiasis among patients who present with cough, fever, hemoptysis, and eosinophilia.

Acknowledgments

Potential conflicts of interest. All authors: no conflicts.

References

1. Castilla EA, Jessen R, Sheck DN, Procop GW. Cavitary mass lesion and recurrent pneumothoraces due to *Paragonimus kellicotti* infection: North American paragonimiasis. *Am J Surg Pathol* **2003**;27:1157–60.
2. Liu Q, Wei F, Liu W, Yang S, Zhang X. Paragonimiasis: an important food-borne zoonosis in China. *Trends Parasitol* **2008**;24:318–23.
3. Ward HB. On the presence of *Distoma westermani* in the United States. *Vet Mag* 1894;1:355–7. Available at: <http://digitalcommons.unl.edu/cgi/viewcontent.cgi?article=1001&context=zoalabstud>. Accessed 23 July 2009.
4. Watson TG, Nettles VF, Davidson WR. Endoparasites and selected infectious agents in bobcats (*Felis rufus*) from West Virginia and Georgia. *J Wildl Dis* **1981**;17:547–54.
5. Cole RA, Shoop WL. Helminths of the raccoon (*Procyon lotor*) in western Kentucky. *J Parasitol* **1987**;73:762–8.
6. Davidson WR, Nettles VF, Hayes LE, Howerth EW, Couvillion CE. Diseases diagnosed in gray foxes (*Urocyon cinereoargenteus*) from the southeastern United States. *J Wildl Dis* **1992**;28:28–33.
7. Ramsden RO, Presidente PJ. *Paragonimus kellicotti* infection in wild carnivores in southwestern Ontario. I. Prevalence and gross pathologic features. *J Wildl Dis* **1975**;11:136–41.
8. Ameel DJ. More data on the lung fluke, *Paragonimus*, in North America. *Science* **1931**;74:493–4.
9. Ward HB. A second case of *Distoma westermani* in the United States. *Vet Mag* 1895;2:87–9. Available at: <http://digitalcommons.unl.edu/cgi/viewcontent.cgi?article=1006&context=zoalabstud>. Accessed 23 July 2009.
10. Ward HB. Data for the determination of human entozoa—II. *Trans Am Microsc Soc* **1908**;28:177–201. Available at: <http://www.jstor.org/stable/3220909?origin=JSTOR-pdf>. Accessed 23 July 2009.
11. Blair D, Xu ZB, Agatsuma T. Paragonimiasis and the genus *Paragonimus*. *Adv Parasitol* **1999**;42:113–222.
12. Ishii Y. Differential morphology of *Paragonimus kellicotti* in North America. *J Parasitol* **1966**;52(5):920–5.
13. Iwagami M, Monroy C, Rosas MA, et al. A molecular phylogeographic study based on DNA sequences from individual metacercariae of *Paragonimus mexicanus* from Guatemala and Ecuador. *J Helminthol* **2003**;77:33–8.
14. Doanh PN, Shinohara A, Horii Y, Habe S, Nawa Y, Le NT. Discovery of *Paragonimus proliferus* in northern Vietnam and their molecular phylogenetic status among genus *Paragonimus*. *Parasitol Res* **2008**;102:677–83.
15. Sogandares-Bernal F. Studies on American paragonimiasis. I. Age immunity of the snail host. *J Parasitol* **1965**;51:958–60.
16. Keiser J, Utzinger J. Emerging foodborne trematodiasis. *Emerg Infect Dis* **2005**;11:1507–14.
17. Beland JE, Boone J, Donevan RE, Mankiewicz E. Paragonimiasis (the lung fluke): report of four cases. *Am Rev Respir Dis* **1969**;99:261–71.
18. Pachucki CT, Levandowski RA, Brown VA, Sonnenkalb BH, Vruno MJ. American paragonimiasis treated with praziquantel. *N Engl J Med* **1984**;311:582–3.
19. Mariano EG, Borja SR, Vruno MJ. A human infection with *Paragon-*

- imus kellicotti* (lung fluke) in the United States. *Am J Clin Pathol* **1986**;86:685–7.
20. Procop GW, Marty AM, Scheck DN, Mease DR, Maw GM. North American paragonimiasis: a case report. *Acta Cytol* **2000**;44:75–80.
 21. DeFrain M, Hooker R. North American paragonimiasis: case report of a severe clinical infection. *Chest* **2002**;121:1368–72.
 22. Madariaga MG, Ruma T, Theis JH. Autochthonous human paragonimiasis in North America. *Wilderness Environ Med* **2007**;18:203–5.
 23. Boe DM, Schwarz MI. A 31-year-old man with chronic cough and hemoptysis. *Chest* **2007**;132:721–6.
 24. Sharma OP. The man who loved drunken crabs: a case of pulmonary paragonimiasis. *Chest* **1989**;95:670–2.
 25. Nana A, Bovornkitti S. Pleuropulmonary paragonimiasis. *Semin Respir Med* **1991**;12:46–54.
 26. Chang HT, Wang CW, Yu CF, Hsu CF, Fang JC. Paragonimiasis: a clinical study of 200 adult cases. *Chin Med J* **1958**;77:3–9.
 27. Singh TS, Mutum SS, Razaque MA. Pulmonary paragonimiasis: clinical features, diagnosis and treatment of 39 cases in Manipur. *Trans R Soc Trop Med Hyg* **1986**;80:967–71.
 28. Shim YS, Cho SY, Han YC. Pulmonary paragonimiasis: a Korean perspective. *Semin Respir Med* **1991**;12:35–45.
 29. Im JG, Kong Y, Shin YM, et al. Pulmonary paragonimiasis: clinical and experimental studies. *Radiographics* **1993**;13:575–86.
 30. Shih YC, Ch'En YH, Chang YC. Paragonimiasis of central nervous system: observations on 76 cases. *Chin Med J* **1958**;77:10–9.
 31. Kagawa FT. Pulmonary paragonimiasis. *Semin Respir Infect* **1997**;12:149–58.
 32. Im JG, Whang HY, Kim WS, Han MC, Shim YS, Cho SY. Pleuropulmonary paragonimiasis: radiologic findings in 71 patients. *AJR Am J Roentgenol* **1992**;159:39–43.
 33. Romeo DP, Pollock JJ. Pulmonary paragonimiasis: diagnostic value of pleural fluid analysis. *South Med J* **1986**;79:241–3.
 34. Slemenda SB, Maddison SE, Jong EC, Moore DD. Diagnosis of paragonimiasis by immunoblot. *Am J Trop Med Hyg* **1988**;39:469–71.
 35. Rim HJ, Chang YS, Lee JS, Joo KH, Suh WH, Tsuji M. Clinical evaluation of Praziquantel (Embay 8440; Biltricide) in the treatment of *Paragonimus westermani*. *Kisaengchunghak Chapchi* **1981**;19:27–37.